Wisdom teeth: remove, or wait and see?

Research has not yet settled whether wisdom teeth that cause no pain should be removed.[1] Still, there are facts to help you decide. The final decision is made together with your dentist, looking at your X-rays.

How the tooth sits, and what to consider

Lower back teeth, seen from the cheek side

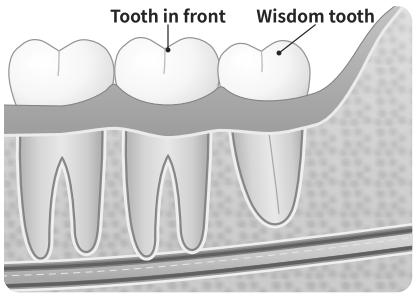

Fully in, straight, and meeting the upper teeth

Often no need to remove

As long as you can clean it well

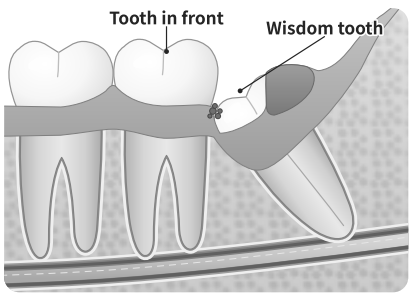

Only partly through the gum

Consider removal

Food and plaque collect next to the tooth in front, which often leads to decay in that tooth or swollen gums[2]

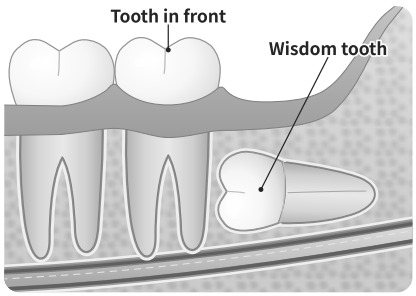

Fully buried in the bone, with no symptoms

Waiting is an option

Check with regular X-rays. Removing it early, with future illness and medicines in mind, is also an option[1]

Gum · Swollen gum · Bone · Nerve and blood vessels for the lower lip and chin · Plaque · Shapes are simplified

Also consider removal if • pain or swelling keeps coming back • the tooth in front has decay or gum disease

If you remove it, younger is better

It gets harder with age

After 25

the risk of problems after removal, and of lasting numbness, goes up[3][5]

- In a US study of about 4,000 people, problems after removal (complications) occurred in **19%** overall, and about **1.5 times** as often over age 25.[3]
- Older age, other health conditions, and roots close to the nerve all increased complications.[4]

Numbness is rare, but becomes more likely with age

Near the lower wisdom teeth run the nerve for feeling in the lower lip and chin (inferior alveolar nerve) and the nerve for feeling in the tongue (lingual nerve). If they are injured during removal, numbness can occur. It is more likely with age[6], the risk of it being permanent is higher from age 25[5], and feeling is less likely to fully return.[7]

0.35%
Lower lip and chin numbness

0.69%
Tongue numbness

In a study of 4,338 teeth, **67% and 72%** recovered fully.[8] In a study of people aged 25 and over only, lower lip and chin numbness was 1.1–1.7%.[9]

From your clinic A clinic stamp is fine for contact details

Phone _____ **Hours** _____ **Notes** _____

Wisdom tooth ☐ Upper right ☐ Upper left ☐ Lower right ☐ Lower left

Today ☐ Consider removal ☐ Wait and see ☐ CT scan ☐ Referral

Next visit ☐ Removal ☐ Follow-up ☐ Check-up Date: Time:

References [1] Ghaeminia H, et al. Surgical removal versus retention for the management of asymptomatic disease-free impacted wisdom teeth. Cochrane Database Syst Rev. 2020;5:CD003879. [2] Revuelta-Cortés P, et al. Clin Oral Investig. 2025;29(1):83. [3] Chuang SK, et al. Age as a risk factor for third molar surgery complications. J Oral Maxillofac Surg. 2007;65(9):1685-1692. [4] Bui CH, et al. J Oral Maxillofac Surg. 2003;61(12):1379-1389. [5] Nguyen E, et al. J Oral Maxillofac Surg. 2014;72(12):2394-2401. [6] Leung YY, Cheung LK. Int J Oral Maxillofac Surg. 2011;40(1):1-10. [7] Queral-Godoy E, et al. Oral Surg Oral Med Oral Pathol Oral Radiol Endod. 2005;99(3):259-264. [8] Cheung LK, et al. Int J Oral Maxillofac Surg. 2010;39(4):320-326. [9] Haug RH, et al. J Oral Maxillofac Surg. 2005;63(8):1106-1114.

Written by a practising dentist (Zubora Ha Lab, Japan) · November 2026 edition

If your clinic's instructions differ, follow your clinic. Free to use; terms of use: zubora-lab.com/sheets/ (Japanese)

Starting a major treatment? See your dentist first.

Illness or medicines can make removal harder

Even if you are well now

Radiation therapy to the head or neck

A review of people who had teeth removed after radiation therapy found that the jawbone died (osteoradionecrosis) in **about 7%**. The risk was higher when removing lower teeth that had received a high dose.[10]

Bone medicines

If you are about to start (e.g. for osteoporosis)

Bisphosphonates and denosumab are the main causes of medicine-related jawbone death.[13] It is rare (0.03% and 0.1% in the package inserts)[11][12], but **extractions should be done before you start, as far as possible.**[11][12][13]

Bone medicines

If you already take them

In principle, extractions are done without pausing the medicine.[13] **Don't stop it on your own.** Stopping denosumab in particular can make spinal fractures more likely.[12]

Bring your medicine record to the dentist too. Whether you take bone medicines can change the decision about extraction.[11][12] Talk to both the doctor who prescribes your medicine and your dentist.

On the day of removal

Questions patients often ask

Q Will I need to stay in hospital?

Usually not. Most are removed as an outpatient, under local anesthesia. With general anesthesia, a hospital stay may be needed.

Q Work or school?

On average, people could not go about their normal day for 1.4 days (half for 1 day or less).[14] Choose a day **when the next day is off**.

Q Swelling and pain?

Pain and swelling usually **peak on days 1–2** and are said to last about 1 week to 10 days. One study found they lasted 3.6 days on average.[15]

Q "The nerve is close"

A CT scan (a 3D X-ray) may be taken to check the position. A CT scan does not reduce the risk of numbness.[16] It is used to plan the removal and explain the risks.

Being referred to a hospital oral surgery department does not necessarily mean the tooth is dangerous.

Common myths

Myth **"It doesn't hurt, so it's fine forever."** In teeth in front of buried lower wisdom teeth, **about 30%** had decay on the side facing the wisdom tooth (review).[2] The tooth in front can be damaged without pain.

Myth **"The swelling went down, so it's healed."** Inflammation around a wisdom tooth (pericoronitis) often comes back, even after it settles.

When to see a dentist

Go now, even after hours

- Sudden **severe swelling**
- **Can't open your mouth, can't swallow, or trouble breathing**

Book soon

- **Pain or swelling** around a wisdom tooth
- Pain or swelling that **keeps coming back**
- **About to start bone medicines or radiation therapy** to the head or neck

Ask at your next check-up

- No pain, but you want to know whether to remove it
- Only partly through the gum and hard to clean

Clinic contact (stamp is fine)

Notes

References ([1]–[9] on page 1)
[10] Nabil S, Samman N. Int J Oral Maxillofac Surg. 2011;40(3):229-243. [11] Teijin Pharma. Bonalon (alendronate) 35 mg tablets, package insert (revised Jan 2023). [12] Daiichi Sankyo. Pralia (denosumab) 60 mg syringe, package insert (revised Nov 2023). [13] Japanese Allied Committee on Osteonecrosis of the Jaw. Position paper 2023 on medication-related osteonecrosis of the jaw. [14] Bienstock DA, et al. J Oral Maxillofac Surg. 2011;69(5):1272-1277. [15] Starch-Jensen T, et al. J Craniomaxillofac Surg. 2023;51(10):635-643. [16] de Toledo Telles-Araújo G, et al. Clin Oral Investig. 2020;24(3):1137-1149.

Written by a practising dentist (Zubora Ha Lab, Japan) · November 2026 edition

If your clinic's instructions differ, follow your clinic. Free to use; terms of use: zubora-lab.com/sheets/ (Japanese)