The bumps at the back of your tongue may be a normal part of it.

Sometimes what looked worrying in the mirror turns out to be a shape everyone's tongue has. On the other hand, some things that are easy to ignore because they don't hurt should be seen early.

Normal tongue shapes often mistaken for cancer

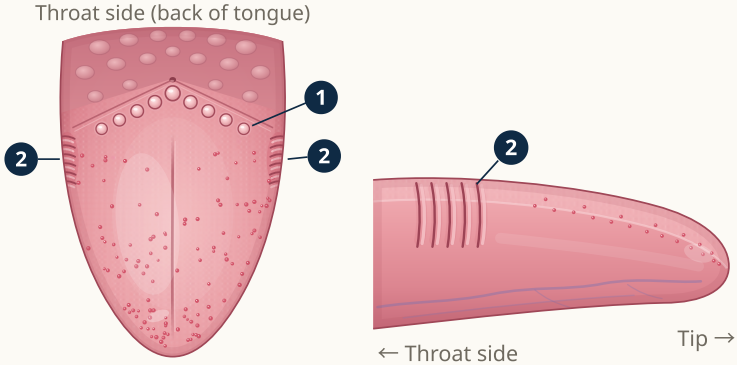

Tip of tongue
Seen from above

Tongue moved to the side, seen from the side

As seen in a mirror. Shape and size vary from person to person

1 Circumvallate papillae

Round bumps at the back of the tongue, lined up in a V that points toward the throat. You may see them when you stick your tongue far out.

2 Foliate papillae

Vertical folds on the side of the tongue, near the throat. You can see them by moving your tongue to the side. They are on both sides.

A Japanese study of people who saw an ear, nose and throat doctor about "something wrong" in their mouth found that the most common thing mistaken for a problem was **the circumvallate papillae everyone has.**[1]

Normal shapes vs. things to have checked

Probably a normal shape

- The same on **both sides**[2]
- Not hard
- Not getting bigger

Have it checked

- On **only one side** of the tongue[2]
- **Growing quickly**, **hard** around it, or **no clear border** with the area around it[3]
- Something you've had for a while that is getting bigger or harder[3]

It's hard to tell for yourself. Next time you notice something, ask your dentist **"What is this?"**

Besides the tongue, some people have **a hard bony bump in the middle of the roof of the mouth or inside the lower teeth (torus)**. It is mainly removed when it gets in the way of treatment, such as making dentures.[4]

From your clinic A clinic stamp is fine for contact details

Phone _____

Opening hours _____

Location _____

Our view ☐ Normal shape ☐ Mouth ulcer ☐ Oral thrush ☐ Lichen planus ☐ Leukoplakia ☐ Mucocele ☐ Torus ☐ Other ( )

Next ☐ Monitor ☐ Biopsy ☐ Referral Date: Time:

References [1] Matsumoto A, et al. Oral "abnormalities" reported by patients. Jibi to Rinsho. 2007;53(5):242-250 (in Japanese). [2] Hennessy BJ. Sores and lumps. MSD Manual Consumer Version, Japanese edition (updated Apr 2024, accessed Nov 2026). [3] Japanese Society of Oral and Maxillofacial Surgeons. Diseases we treat: malignant tumors (accessed Nov 2026). [4] García-García AS, et al. Current status of the torus palatinus and torus mandibularis. Med Oral Patol Oral Cir Bucal. 2010;15(2):e353-e360.

Written by a practising dentist (Zubora Ha Lab, Japan) · November 2026 edition

If your clinic's instructions differ, follow your clinic. Free to use; terms of use: zubora-lab.com/sheets/ (Japanese)

Not healed in 2 weeks? See a dentist or oral surgeon.

Common white patches and lumps

For white patches, **whether it rubs off** is one clue. But appearance alone can't decide.[5]

Oral thrush

Wipes off

An infection caused by an overgrowth of a yeast (Candida) that normally lives in the mouth. The area underneath is red. It is treated with antifungal medicine.[5]

Oral lichen planus

White lacy pattern inside the cheek

White lines form a lace-like pattern with redness around it. Rarely, it can turn into cancer (about 1.4% in a review of studies).[5][6] Have it checked regularly.

Leukoplakia

Doesn't rub off

Thought to be linked to irritation such as tobacco, alcohol and poorly fitting dentures.[5] In a review of studies, about 6.6% turned into cancer.[7] It needs long-term follow-up.[5]

Mucocele

Clear blister

A clear to bluish blister inside the lower lip or under the tongue. It forms when, for example, biting the lip blocks or breaks a saliva duct and saliva collects.[8]

Common myths

Myth **"My mouth hurts. It might be cancer."** The most common painful sore is an ordinary mouth ulcer. It heals in 1–2 weeks.[5]

Myth **"It doesn't hurt, so it's fine."** Unexplained red or white changes, raw areas and lumps can be signs of cancer, especially when they don't hurt.[2]

Myth **"I just noticed it, so it must be new."** You may have only just noticed a shape that has always been there.[1] Even if it has been there a while, have it checked if it gets bigger or harder.[3]

When to be seen

See a dentist or oral surgeon soon

- A lump, mouth ulcer or wound that **hasn't healed in 2 weeks**[9]
- A hard lump, something growing quickly, or bleeding[3]
- A red patch, or a mixed red and white patch[9][10]
- A bump on only one side of the tongue[2]
- A lump in the neck that doesn't go away[10]

OK to wait and see

- An ordinary mouth ulcer (aphthous ulcer). Heals in 1–2 weeks[5]
- Bumps or folds at the back of the tongue that look the same on both sides. If you're curious, ask at your next dental visit[2]

What is a biopsy for?

When appearance alone can't decide, part or all of it is removed and examined under a microscope. Being offered a biopsy does not by itself mean it is cancer.

Clinic contact (stamp is fine)

Notes

References

[1] Matsumoto A, et al. Jibi to Rinsho. 2007;53(5):242-250. [2] Hennessy BJ. Sores and lumps. MSD Manual Consumer Version, Japanese edition. [3][5][8] Japanese Society of Oral and Maxillofacial Surgeons. Diseases we treat (malignant tumors / oral mucosal diseases / cysts) (accessed Nov 2026). [6] González-Moles MÁ, et al. Cancers (Basel). 2024;16(3):608. [7] Pimenta-Barros LA, et al. Oral Dis. 2025;31(1):69-80. [9] Nagoya City. Oral cancer self-check. 2025. [10] NICE. Suspected cancer: recognition and referral (NG12).

Written by a practising dentist (Zubora Ha Lab, Japan) · November 2026 edition

If your clinic's instructions differ, follow your clinic. Free to use; terms of use: zubora-lab.com/sheets/ (Japanese)