# Knocked-out tooth: don't touch the root, put it in milk.

Injured teeth can often be saved if treated quickly and properly.[1] Even at night or on a holiday, get seen as soon as you can. If possible, go to the emergency department of a hospital with an oral surgery department.

**!** If the person **hit their head, is not fully alert, or feels nauseous**, see a doctor before dealing with the teeth.[1]

## If a tooth is knocked out

Time out of the mouth and how it was kept matter most[1]

1. **Stay calm and find the tooth**[2]
2. **Hold it by the crown (the white part). Don't touch the root**[2]
   The root surface still has cells that attach the tooth to the bone
3. **If it's dirty, rinse it briefly in milk or saline**[2]
   Don't scrub it
4. **Put it in cold milk**[1]
   Regular milk is best; avoid long-life (UHT) or low-fat milk
5. **No milk?** Keep it from drying out: a tooth storage solution, saline, or plastic wrap[1][2]
6. **Go to a dentist right away**[2]

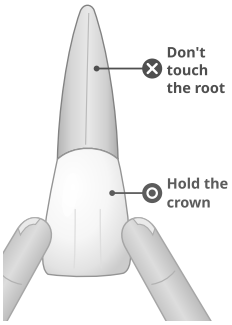


To protect the cells on the root surface

### What not to do

- **Scrub it**
  This damages the important cells on the root surface[2]
- **Wrap it in a tissue or handkerchief**
  If it dries out, the cells on the root die[2]
- **Leave it in tap water**
  Water isn't good for storing teeth (though it's better than letting it dry) [2][3]

**No number of minutes is guaranteed to be safe. The sooner, the better.**

| | |
|---|---|
| **~15min** | Put back on the spot within this time: the root cells are likely still alive |
| **60+min** | Kept dry this long: the cells are unlikely to survive[2] |

International guidelines also recommend putting the tooth back in its socket on the spot.[2] But this is hard if you're not used to it, so **don't force it — put the tooth in milk and get to a dentist quickly**.

### If a child's baby tooth is knocked out

A baby tooth is not put back if this could damage the adult tooth growing underneath.[1] But don't just wait and see because "it's only a baby tooth": an injury to a baby tooth can affect the adult tooth below.[1] **See a dentist even for baby teeth.**

### If a tooth is chipped

**Don't throw away the broken piece** — bring it with you, in water so it doesn't dry out.[1] Even if it's only a small chip or doesn't hurt, see a dentist right away. Whether the chip is close to the nerve can't be judged without looking.

**From your clinic** A clinic stamp is fine for contact details

**Phone** _____ **Injury** ☐ Chipped ☐ Cracked root ☐ Loose ☐ Displaced ☐ Knocked out

**Hours** _____ **Today** ☐ Rebuilt ☐ Nerve treatment ☐ Put back & splinted ☐ Watch

**Injured tooth** _____ **Next check** ☐ 1 month ☐ 3 months ☐ 1 year Date: Time:

**References** [1] Japanese Society of Dental Traumatology. Guidelines for the treatment of traumatic dental injuries (revised Oct 2023). [2] Fouad AF, et al. International Association of Dental Traumatology guidelines for the management of traumatic dental injuries: 2. Avulsion of permanent teeth. Dent Traumatol. 2020;36(4):331-342. [3] Zhang N, et al. Network Meta-Analysis of 10 Storage Mediums for Preserving Avulsed Teeth. Front Med (Lausanne). 2021;8:749278.

**Written by a practising dentist (Zubora Ha Lab, Japan) · November 2026 edition**

If your clinic's instructions differ, follow your clinic. Free to use; terms of use: zubora-lab.com/sheets/ (Japanese)

# Even if it doesn't hurt, we follow it for a year.

## Types of injury and treatment Looks alone can't tell, so get checked

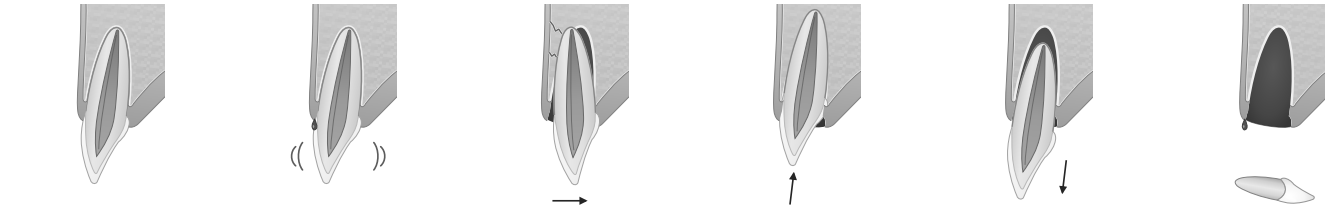

**Normal**
Sits in its socket in the bone

**Subluxation**
Same position, but loose

**Lateral luxation**
Pushed sideways. The bone may break

**Intrusion**
Pushed in. Looks shorter

**Extrusion**
Pushed out. Looks longer

**Avulsion**
Knocked out completely

Socket where the tooth sat · Bone that holds the tooth · Crack in the bone

An upper front tooth seen from the side. The left side is the lip side. Shapes are simplified.

**Chipped** crown fracture (visible part)

**The dentist**: reattaches the piece or rebuilds the shape with white resin; treats the nerve if it is exposed[1]

**Cracked** root fracture (inside the gum)

**The dentist**: it is hard to see, so it is checked by X-ray. If shifted, it is put back and splinted[1]

**Loose** subluxation

**The dentist**: usually watches it. If biting hurts, it is splinted for 1–2 weeks[1]

**Shifted, pushed in or out** luxation

**The dentist**: puts it back as soon as possible and splints it[1]

**Knocked out** avulsion

**The dentist**: puts it back (replantation) as soon as possible and splints it[1]

**Several teeth move together** possible fracture of the bone

**The dentist**: puts the bone back in place and splints it[1]

**1 year**
at least — how long an injured tooth is followed

Even if it seems fine right after the injury, the tooth may later turn **dark or gray**. If the blood vessels supplying the nerve are torn and the nerve dies, the tooth changes color. Then root canal treatment is done.[1] This can happen even if the tooth was only loose. **It is checked at 1 month and 3 months, then followed for at least a year.**[1]

## When to see a dentist

**All of these: go right away** Even at night or on a holiday

- **A tooth is knocked out, shifted or pushed in**
- **A chip shows a pink spot (the nerve)**[1]
- A small chip, even if painless (bring the piece)
- Later turns **dark or gray**[1]
- **Several teeth move together**, or a cut in the gum won't stop bleeding[1]
- **A tooth is loose or hurts when biting**
- No change in looks or pain (still have it followed for a year)[1]

**Be prepared** In contact sports such as rugby, martial arts and basketball, wearing a mouthguard is linked to fewer dental injuries.[4] For places where milk isn't handy, such as club activities or camping, it's a good idea to keep a tooth storage solution in your first-aid kit.

Clinic contact (stamp is fine)

Notes

**References**

[1] Japanese Society of Dental Traumatology. Guidelines for the treatment of traumatic dental injuries (revised Oct 2023). [2] Fouad AF, et al. Dent Traumatol. 2020;36(4):331-342. [3] Zhang N, et al. Front Med (Lausanne). 2021;8:749278. [4] Fernandes LM, et al. The use of mouthguards and prevalence of dento-alveolar trauma among athletes: A systematic review and meta-analysis. Dent Traumatol. 2019;35(1):54-72.

**Written by a practising dentist (Zubora Ha Lab, Japan) · November 2026 edition**

If your clinic's instructions differ, follow your clinic. Free to use; terms of use: zubora-lab.com/sheets/ (Japanese)